Using Virtual Augmented Reality to Remotely Proctor Overseas Surgical Outreach: Building Long-Term International Capacity and Sustainability

Raj M. Vyas, M.D.
Lohrasb Ross Sayadi, M.D.
David Bendit, B.A.
Usama S. Hamdan, M.D.

Orange, Calif.; and Norwood, Mass.

Background: Cleft lip affects one in 700 children globally, and the prevalence far surpasses capacity to deliver cleft care in underresourced and endemic regions. A hands-on educational presence is needed to promote overseas surgical autonomy, build overseas capacity, and ensure a sustained clinical and educational infrastructure. The goal of this study was to build and assess an augmented reality educational platform that allows a remote yet virtual interactive presence to transfer cleft surgery knowledge/skills to overseas colleagues.
Methods: A prospective study assessing a 13-month overseas augmented reality–based cleft surgery curriculum was conducted. Three semiannual site visits engaged two Peruvian surgeons in evidence-based didactics, on-site cleft surgery, and familiarization with the augmented reality platform. During 10 remote augmented reality visits, a surgeon stationed in United States guided the same Peruvian surgeons through cleft surgery. Quarterly assessments of the Peruvian surgeons were performed using visual analogue scale questionnaires.
Results: Visual analogue scale scores by both the remote and overseas surgeons demonstrated significant, progressive improvement in all facets of cleft lip repair throughout the curriculum. Site visits preferentially built capacity for cleft diagnosis and preoperative counseling ($p < 0.001$), principles of repair ($p < 0.001$), repair technique ($p < 0.02$) and intraoperative decision-making ($p < 0.001$). Remote sessions preferentially developed understanding of cleft operative design/anthropometry ($p < 0.04$), cleft anatomy ($p < 0.01$), and operative efficiency ($p < 0.001$). At 30-month follow-up, no children with cleft lip required transfer to tertiary care centers.
Conclusion: A curriculum that combines on-site training and augmented reality–based hands-on remote teaching can build sustained capacity of comprehensive cleft care in underresourced areas. (*Plast. Reconstr. Surg.* 146: 622e, 2020.)

Cleft lip is a birth defect affecting approximately one in 700 children globally with significantly higher prevalence in endemic regions.[1] It affects facial appearance, carries significant social stigma,[2] and interferes with the functions of speech and feeding. Operative repair of the cleft lip and nasal deformity has optimal results when performed between age 3 and 6 months. Unfortunately, in underresourced and/or endemic areas, the incidence and prevalence of cleft deformity far surpass the regional capacity to deliver needed cleft care. Although difficult to quantify,[3,4] the worldwide disease burden of children, adolescents, and adults with unrepaired cleft deformity is astounding.

Although scores of groups participate in overseas cleft outreach, the vast majority do so

From the Department of Plastic Surgery, University of California, Irvine; and the Global Smile Foundation.
Received for publication July 27, 2019; accepted May 21, 2020.

DOI: 10.1097/PRS.0000000000007293

Disclosure: *The authors have no financial interest to declare in relation to the content of this article.*

Related digital media are available in the full-text version of the article on www.PRSJournal.com.

A Video Discussion by Roberto Flores, M.D., accompanies this article. Go to PRSJournal.com and click on "Video Discussions" in the "Digital Media" tab to watch.

sporadically and focus only on short-term needs. In recent years, the major global cleft outreach organizations have invested resources to build longer term capacity and sustainability of cleft care. Operation Smile, for example, has partnered with the most endemic regions of the world to establish comprehensive cleft centers.[5–7] SmileTrain freely disseminates its digital instructional videos and online surgical simulators to illustrate state-of-the art techniques.[8–11] The Global Smile Foundation has contributed a video atlas of cleft surgery[12] and international protocols for resource optimization,[13] quality improvement,[12,14] patient safety,[15] and emergency preparedness.[16] Still, all agree that a consistent, hands-on presence is needed to truly promote overseas surgical autonomy, build overseas capacity for comprehensive cleft care, and ensure a sustained clinical and educational infrastructure.

Augmented reality is a blending of the physical and virtual worlds that has emerged as a valuable tool in the field of surgery with exciting new possibilities in global health outreach.[17–21] Augmented reality allows an expert cleft surgeon who is committed to overseas outreach to easily maintain a hands-on overseas presence without leaving his or her own home institution. Such augmented reality–based remote sessions provide a live and interactive presence, enabling continued education and proctoring of overseas colleagues that can build on knowledge and skills transferred during outreach trips.

To date, no study has tested the safety, efficacy, and long-term promise of using augmented reality to remotely teach overseas cleft surgery. We sought to develop and measure the effectiveness of using an intraoperative augmented reality platform as the cornerstone of a 13-month cleft surgery education curriculum instituted in Trujillo, Peru. This study was performed in conjunction with the Peruvian EsSalud Hospital System and with the explicit support of the Peruvian Ministry of Health. It was made possible by a collaborative effort between the Global Smile Foundation, a not-for-profit cleft outreach organization composed of multidisciplinary cleft providers, and two technology startups [Vipaar LLC (Birmingham, Ala.) and Proximie LLC (Boston, Mass.)]. Funding was provided by grants from the American Society of Plastic Surgeons and the Cleft Palate Foundation.

PATIENTS AND METHODS

Augmented Reality Technology

An augmented reality technology platform was developed to provide "hands-on" remote education and guidance during international cleft lip surgery. This technology creates a virtual interactive presence through which cleft-trained surgeons are remotely connected—in real time—to dedicated overseas partners. In each operation, a small tablet with video capability is mounted to an operating room table in a nonobtrusive position. [**See Figure, Supplemental Digital Content 1**, which shows the augmented reality operating room setup at an international site. A small tablet (*blue arrow*) with video capability is shown mounted on an operating room table in a nonobtrusive position, ***http://links.lww.com/PRS/E233***.] Using augmented reality technology (downloaded to the tablet as a software application) and reliable Wi-Fi, the system transmits continuous audio/video of the procedure to the remote cleft-trained surgeon. In turn, the remote surgeon observes the ongoing overseas operation and places his or her hands and instruments between a web camera and black underlay (the remote virtual field). Augmented reality technology merges audio and video from the overseas operation and the remote surgeon's virtual field into one integrated livestream, viewed simultaneously by both surgeons. This virtual interactive presence allows the remote surgeon to effectively "scrub in" and assist in the overseas operation (Fig. 1). [**See Figure, Supplemental Digital Content 2**, which shows augmented reality proctoring. This figure demonstrates the merging of audio and video from the overseas operation and the remote surgeon's virtual field into one integrated augmented reality livestream, ***http://links.lww.com/PRS/E234***. **See Video (online)**, which demonstrates augmented reality proctoring during cleft surgery in Peru with international surgeon testimonials.]

Proof-of-Concept Study

A proof-of-concept pilot study was conducted to validate the use of augmented reality technology as a remote yet hands-on teaching modality for infant cleft lip repair. The technology was used in nine operations across four international Global Smile Foundation partner sites (i.e., El Salvador, Ecuador, Lebanon, and Peru). During this pilot investigation, both the remote and overseas surgeons were experienced in cleft repair. Likert surveys completed by both the remote and overseas surgeons found the augmented reality platform to be safe, reliable, and effective (data not shown). The augmented reality system was also accurate and precise, as the remote and overseas surgeons differed by less than 1 mm when identifying and "marking" the 13 lip and nasal anthropometric

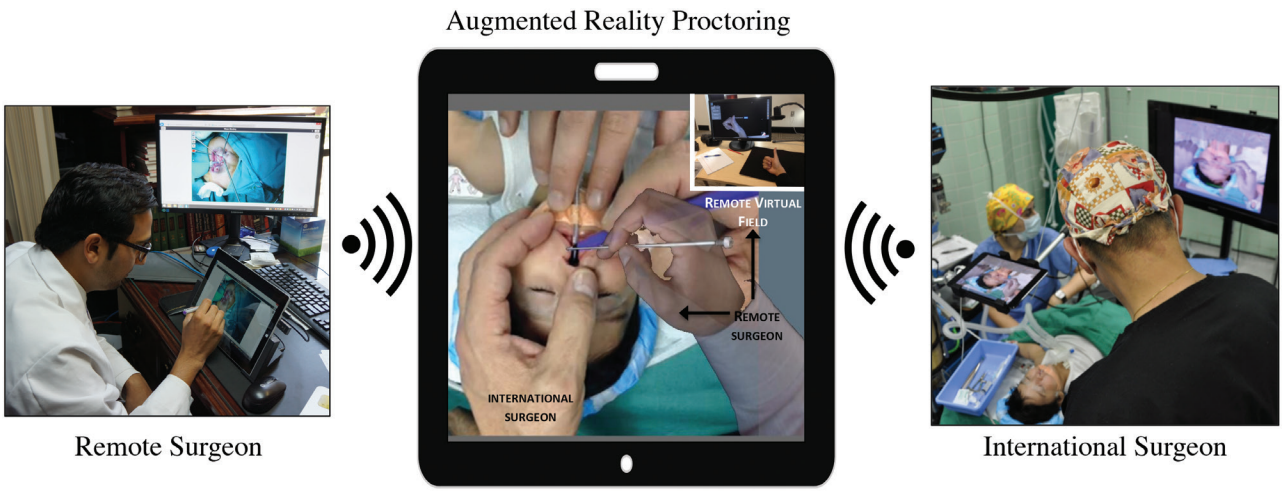

Fig. 1. Augmented reality proctoring. Merging of audio and video from the overseas operation and the remote surgeon's virtual field into one integrated augmented reality livestream is demonstrated.

landmarks integral to designing an infant's cleft lip repair (Fig. 2). Average operating room time was 171 minutes and average procedure time (including remote marking and proctoring) was 146 minutes; both these times were significantly higher than age, diagnosis, and surgeon-matched Global Smile Foundation historic controls (152 minutes and 131 minutes, respectively; $p < 0.05$). There were no patient complications related to the mounted camera, technology platform, or remote virtual proctoring.

Study Design

A 13-month augmented reality–based longitudinal education curriculum was instituted in Trujillo, Peru. This curriculum consisted of three semiannual site visits and 10 remote visits using augmented reality to remotely guide cleft lip

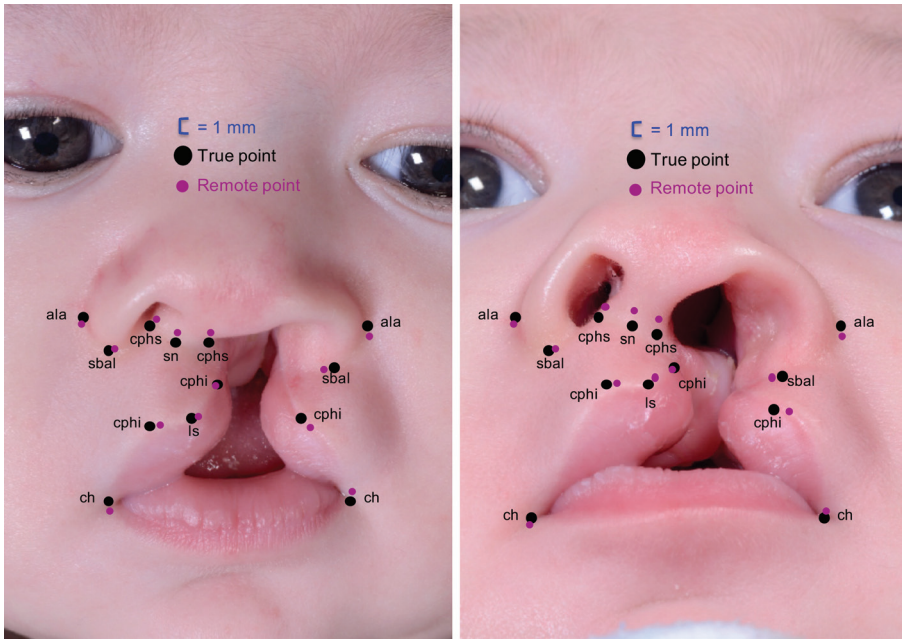

Fig. 2. Concordance of lip and nasal anthropometry. Anterior and subnasal views of unilateral complete cleft lip deformity. Remote and overseas surgeons independently identified 13 important anthropometric landmarks for nasolabial repair. The average accuracy of each remotely marked point differed by less than 1 mm compared to the overseas surgeons' "true" marked points ($n = 9$ pilot study) (range, 0.5 to 1.5 mm).

repair (Fig. 3). At the semiannual site visits, the lead author provided two Peruvian surgeons with evidence-based didactic instruction in cleft care, engaged them in 26 on-site cleft operations (21 unilateral and five bilateral), and familiarized them with the augmented reality system. During the remote visit sessions, the (same) remote surgeon stationed in California guided the same Peruvian surgeons through a total of 17 cleft operations (14 unilateral and three bilateral) using the augmented reality system. All patient families consented to participation in the study and authorized use of resulting video and photographic material. The principles outlined in the Declaration of Helsinki were followed to ensure ethical treatment of all subjects. The study design was reviewed and approved by the Institutional Review Board of the University of California.

A visual analogue scale was designed and used to assess longitudinal improvements between the two Peruvian surgeons across seven facets of cleft lip repair: (1) cleft diagnosis and preoperative counseling/preparation; (2) operative design and cleft anthropometry; (3) operative anatomy; (4) intraoperative decision-making; (5) operative quality, principles of repair; (6) operative quality, techniques of repair; and (7) operative efficiency. [**See Figure, Supplemental Digital Content 3**, which shows visual analogue scale (*VAS*) questionnaire for international and remote surgeons. The visual analogue scale was used to assess longitudinal improvements between the two Peruvian surgeons across facets of cleft lip repair, ***http://links.lww.com/PRS/E235***.] The Peruvian surgeons were asked to score themselves across these seven components on a scale of 1 (inferior) to 10 (mastery) before the study began, after each of the three site visits, and four times after completion of a series of two or three remote visits (Fig. 3). The remote surgeon was also asked to independently score the two Peruvian surgeons at these same time points. As such, visual analogue scale scores were assessed to calculate the degree of improvement after each site visit and after each series of remote visits. A cumulative mean improvement score irrespective of surgeon and composed of both remote and self-scores was calculated for each visit. Remote and self-surgeon mean improvement scores were also independently tabulated and analyzed.

International Site Description

Trujillo, Peru, has been a Global Smile Foundation partner site since 2006. Peru's EsSalud hospital system is its largest public health care provider, serving over 11 million Peruvians. Despite state-sponsored health coverage for children with cleft lip deformity, access to providers is grossly limited outside of Lima, the nation's capital and most densely populated district. A partnership was established with two Peruvian plastic surgeons at EsSalud's Hospital de Alta Complejidad de La Libertad in Trujillo, Peru. The two Peruvian plastic surgeons at this medical center who were recruited to participate in our study had no specialized cleft/craniofacial training before this intervention. Previous attempts had been made by Global Smile Foundation surgeons to teach surgeons at this site during annual outreach trips, with variable outcomes and short-lasting success. As such, in the absence of international outreach providers, many children with cleft lip in the Trujillo area either received treatment in Lima, Peru (a 10-hour bus ride), or simply went without treatment. Therefore, this site was ideal for instituting our augmented reality–based longitudinal educational curriculum.

Remote Site Description

The remote cleft surgeon was stationed at the University of California during all remote visits. This site was equipped with an augmented reality platform that registered the remote surgeon's hands and instruments, merging them into a live digital representation with the overseas operative field (Fig. 1). This augmented reality representation was simultaneously viewable at both the remote and international sites. Using this system, the remote surgeon could accurately guide the overseas surgeons through cleft surgery.

Statistical Analysis

Statistical analysis was performed using chi-square for comparison between binary variables and a single-tailed *t* test assuming equal population

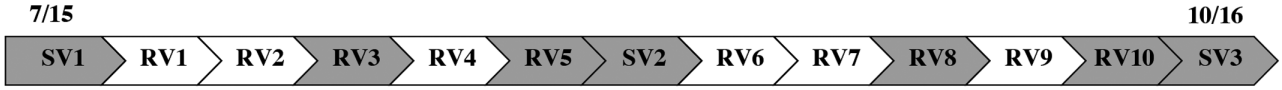

Fig. 3. Augmented reality–based longitudinal educational curriculum. Timeline of proposed 13-month augmented reality–based longitudinal educational curriculum. Numbered site visits (*SV*) and remote visits (*RV*) are shown. *Gray arrows* indicate the visits after which visual analogue scale scores were obtained.

variance for comparison between quantitative variables. A value of $p < 0.05$ was considered statistically significant.

RESULTS

Because of logistical challenges, the planned 13-month curriculum was instead completed in 16 months. A total of 43 children underwent cleft lip repair during this period: 26 on-site cleft lip repairs (21 unilateral and five bilateral) and 17 remote cleft lip repairs (14 unilateral three bilateral). Visual analogue scale scoring by both the remote and overseas surgeons demonstrated a progressive trend toward improvement in all seven facets of cleft lip repair (Figs. 4 and 5). (**See Figure, Supplemental Digital Content 4**, which shows a comparison of remote and site visits on improvement of cleft repair. Comparison in overseas surgeons' mean improvement in cleft lip repair, as measured by the visual analogue scale, after remote visits and site visits, ***http://links.lww.com/PRS/E236***. **See Figure, Supplemental Digital Content 5**, which shows surgeon 2 self-scores over the course of the augmented reality–based curriculum demonstrating a significant improvement across the seven aspects of cleft care measured using the visual analogue scale. *SV*, site visit; *RV*, remote visit, ***http://links.lww.com/PRS/E237***. **See Figure, Supplemental Digital Content 6**, which shows the remote surgeon's scoring of surgeon 2's performance over the course of the augmented reality–based curriculum across the seven aspects of cleft care measured using the visual analogue scale. *SV*, site visit; *RV*, remote visit, ***http://links.lww.com/PRS/E238***.) The overseas surgeons indicated greater improvement after site visits compared to remote visits across the following facets of cleft lip repair: cleft diagnosis and preoperative counseling (10.4 versus 0.94; $p < 0.001$), principles of repair (11.4 versus 2.5; $p < 0.001$), repair technique (7.5 versus 4.68; $p < 0.02$), and intraoperative decision-making (12.5 versus 2.81; $p < 0.001$) (Fig. 4). Overseas surgeons indicated a greater improvement after remote sessions compared to site visits in their understanding of cleft operative design/anthropometry (8.44 versus 5.0; $p < 0.04$), cleft anatomy (8.13 versus 3.8; $p < 0.01$), and operative efficiency (7.5 versus 2.9; $p < 0.001$). The same trends were observed when each overseas surgeon's scores were analyzed independently and by the remote surgeon for each overseas surgeon (Figs. 4 and 5).

Of the 43 cases performed, no major complications were reported. One incident of prolabial ischemia requiring suture release, débridement, and closure was encountered in a bilateral cleft lip repaired during a remote session. During the 16-month study period and 30-month follow-up, no cleft patients presenting to EsSalud Hospital System in Trujillo, Peru, were transferred to Lima because of severity of cleft diagnosis. Several children with cleft lip and a syndromic phenotype were transferred for higher level of cardiopulmonary, renal, or musculoskeletal treatment.

DISCUSSION

Conditions that require surgery are a top cause of global disability. With a worsening global shortage of surgeons, this disparity is now a paramount global health concern.[22–26] To address this issue, several outreach organizations have sponsored overseas initiatives that focus on short-term needs. Because of logistic and financial constraints, only a few have concentrated on developing an infrastructure that affords long-term capacity and sustainability. As such, overseas surgeons who receive hands-on training and knowledge transfer during surgical outreach often find that their newfound skills deteriorate or become obsolete because of lack of reinforcement and accountability. Whereas "see one, do one, teach one" is a romantic mantra in domestic surgical training, building international capacity and sustainability requires a more consistent presence and commitment. Repeated expert guidance ensures quality, indoctrinates surgical principles, and refines operative techniques.

Advancements in technology have made long-distance communication among parties rapid, effortless, and affordable. Technologies such as augmented reality enable clinicians to have a remote yet live and interactive digital presence that merges seamlessly with the physical world. Harnessing this power to overcome obstacles in global outreach initiatives is no longer science fiction. In this study, an augmented reality system was used to merge audio and video from the overseas operation and the remote surgeon's virtual field into one integrated livestream viewed simultaneously by both surgeons. This virtual interactive presence allows the remote surgeon to effectively "scrub in" and guide the overseas operation (Fig. 1 and **see Figure, Supplemental Digital Content 1**, ***http://links.lww.com/PRS/E233***, and **Figure, Supplemental Digital Content 2**, ***http://links.lww.com/PRS/E234***). Importantly, we have demonstrated that an augmented reality platform can allow accurate and precise identification (<1 mm) of the intricate surface anatomy of an infant cleft

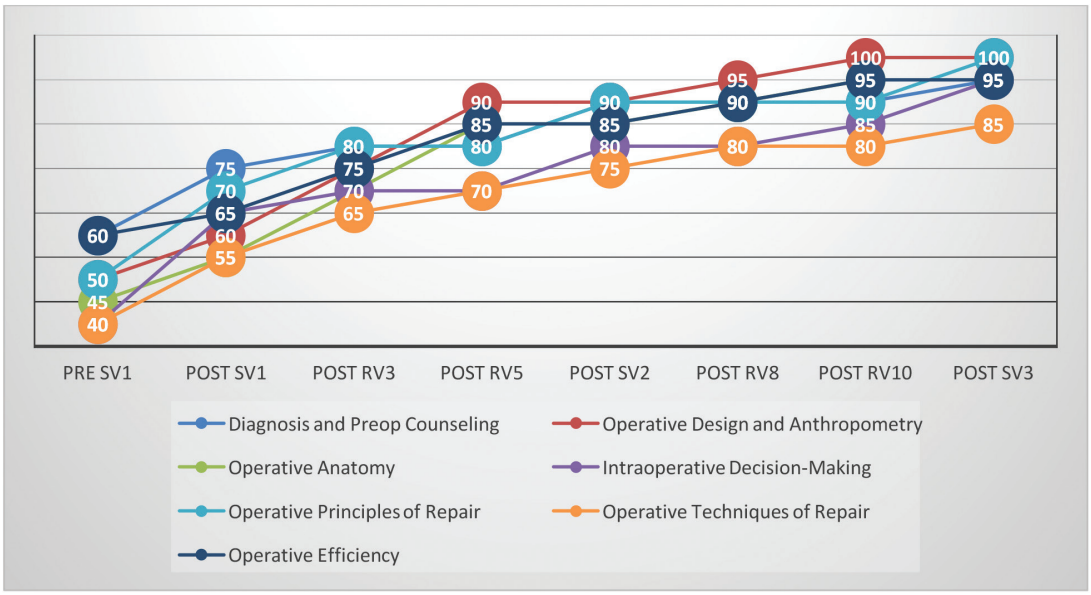

Fig. 4. Surgeon 1 self-score over the course of the augmented reality–based curriculum demonstrating a significant improvement across the seven aspects of cleft care measured using the visual analogue scale. *SV*, site visit; *RV*, remote visit.

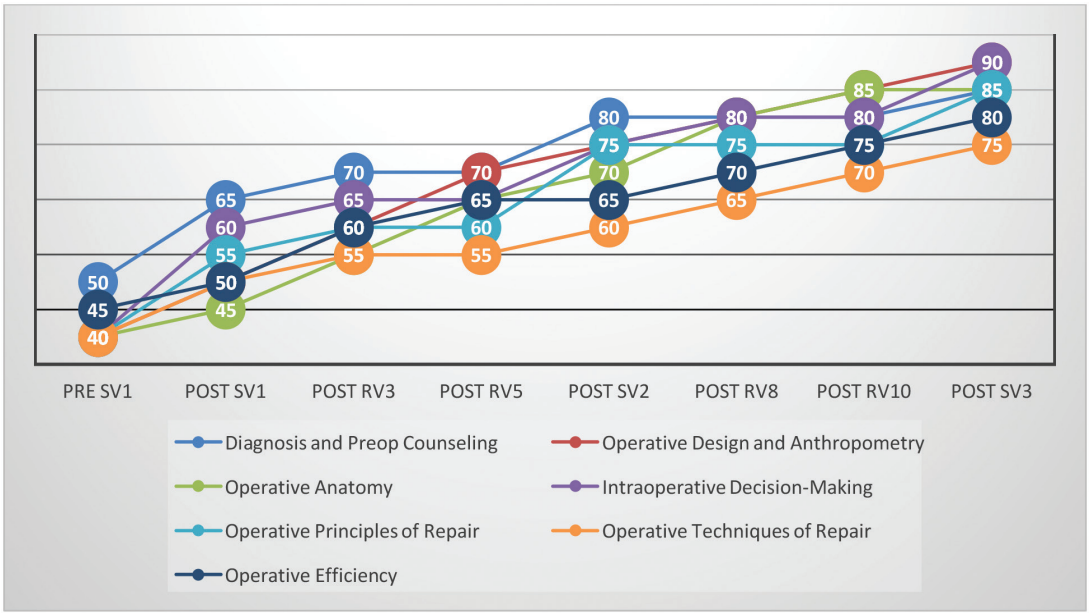

Fig. 5. Remote surgeon's scoring of surgeon 1's performance over the course of the augmented reality–based curriculum across the seven aspects of cleft care measured using the visual analogue scale. *SV*, site visit; *RV*, remote visit.

lip, thereby enabling effective remote operative guidance (Fig. 2).

The present study is the first to implement and measure the effectiveness of using augmented reality to maintain continuity of training for overseas (cleft) surgeons who have partnered with a global outreach organization. Using this augmented reality system, we instituted a curriculum composed of both direct site and remote visits at an EsSalud Hospital in Trujillo, Peru (Fig. 3). This site was preferentially selected because of its endemic burden of unrepaired cleft lips and lack of specialized cleft training among native surgeons. During site visits, an experienced cleft surgeon directly guided cleft surgery performed by the two Peruvian surgeons. The remote visits,

which outnumbered the direct site visits, tested the augmented reality platform and routinely reinforced operative lessons learned during each of the site visits. Using visual analogue score surveys, we found that both overseas surgeons who completed the curriculum improved significantly across all parameters of cleft repair (Figs. 4 and 5 and **see Figure, Supplemental Digital Content 4**, ***http://links.lww.com/PRS/E236***; **Figure, Supplemental Digital Content 5**, ***http://links.lww.com/PRS/E237***; and **Figure, Supplemental Digital Content 6**, ***http://links.lww.com/PRS/E238***). Subanalysis revealed remote visits had a more significant impact on the Peruvian surgeons' understanding of operative design/anthropometry, cleft anatomy, and their operative efficiency, and site visits preferentially improved cleft diagnosis and preoperative counseling, understanding of the principles of repair, repair technique, and intraoperative decision-making. These differences are attributable to the differing nature of site and remote visits. Site visits remain integral in global outreach, as a physical presence is the gold standard for establishing the clear communication and trust needed for knowledge and skill transfer. Still, we demonstrate that augmented reality–based remote visits are safe, reliable, and effective tools for accelerating the transfer of surgical knowledge and skills. The interval improvements noted after remote sessions objectively support the intuitive need for continued surgical guidance that goes beyond an overseas outreach trip. Indeed, a symbiosis of direct knowledge transfer and remote augmented reality proctoring is most effective toward building sustained cleft capacity at global outreach sites.

Augmented reality proctoring enables remote contribution by experts, many of whom cannot participate in outreach initiatives because of limitations in time and funding. The ability to sit in one's office and effortlessly guide live surgery at international sites is an inspiring vision for a variety of busy expert surgeons who are interested in contributing to global health. Native surgeons at these sites can achieve surgical proficiency and autonomy through multiple remote proctoring sessions, thereby gaining the confidence to treat rather than refer patients in severely underresourced settings. Augmented reality technology can also be used to remotely transfer complementary knowledge and skills to associated cleft care providers; we are currently studying the use of augmented reality to support knowledge and skill transfer for presurgical nasoalveolar molding and for nasoendoscopy in evaluating velopharyngeal insufficiency in patients with cleft lip, nose, and palate. Domestically, augmented reality can be used as an educational tool, allowing surgeons across the nation to livestream and interact meaningfully during operations. We envision that this system will facilitate information transfer and idea sharing.

As technology continues to improve, augmented reality will become not only more realistic but also less expensive and more portable. In our study, augmented reality technology merged virtual representations with the physical world onto a separate monitor near the operative field. Setting up and operating this system adds time to surgery. However, new augmented reality systems such as Microsoft Hololens (Microsoft Corp., Redmond, Wash.) allow for this merging to occur in a portable headset, thereby blending the virtual and real world in the operator's field of vision. More primitive wearable technology was trialed during our pilot study (2014) but was found to be of inadequate resolution, focus, and lighting/exposure. The improved portability and more advanced integration of virtual representations afforded by modern augmented reality headset devices will soon widen its adoption and application to surgical education—both domestically and overseas.

This study has several noteworthy limitations. The limited number of overseas surgeons (n = 2) enrolled in the augmented reality–based curriculum might affect the generalizability of our results. Similarly, one experienced cleft surgeon conducted all remote and site visits, and it is likely that differences in teaching techniques among different surgeons will affect the acquisition of surgical skills. Finally, there was no control group for this study (only site visits, no augmented reality remote visits). From a technology standpoint, we were fortunate that our overseas partner had a wireless Internet setup, allowing for the remote augmented reality connection. Similarly, a considerable amount of dedication and buy-in is required by both parties, remote and overseas, to implement both this technology and an effective educational partnership. Our group consisted of surgeons, engineers, and administrative staff from Global Simile Foundation and Proximie, LLC, who traveled to the remote site before study initiation to not only assist with technology setup, but also to help train the overseas staff. Beyond these needs and expenses, grant funding from the American Society of Plastic Surgeons ($10,000) and the Cleft Palate Foundation ($5000) afforded all major study costs: hardware ($2200), augmented reality software license ($7000), and international travel

($4000). Despite these limitations, we believe our findings convincingly demonstrate that the addition of augmented reality–based remote visits to conventional global outreach strategies improves continuity of overseas partnerships, accelerates surgical knowledge transfer, and achieves sustained capacity.

Raj M. Vyas, M.D.
Department of Plastic Surgery
University of California, Irvine School of Medicine
UCI Health
Children's Hospital Orange County
200 South Manchester Avenue, Suite 650
Orange, Calif. 92868
rajv1@uci.edu
Twitter: @uciplasticsurgeryresidency

PATIENT CONSENT

Patients, parents or guardians, and subjects gave written consent for the use of patient images.

REFERENCES

1. Vyas RM, Warren SM. Unilateral cleft lip repair. *Clin Plast Surg.* 2014;41:165–177.
2. Sousa AD, Devare S, Ghanshani J. Psychological issues in cleft lip and cleft palate. *J Indian Assoc Pediatr Surg.* 2009;14:55–58.
3. Tollefson TT, Shaye D, Durbin-Johnson B, Mehdezadeh O, Mahomva L, Chidzonga M. Cleft lip-cleft palate in Zimbabwe: Estimating the distribution of the surgical burden of disease using geographic information systems. *Laryngoscope* 2015;125(Suppl 1):S1–S14.
4. Khajanchi MU, Shah H, Thakkar P, Gerdin M, Roy N. Unmet burden of cleft lip and palate in rural Gujarat, India: A population-based study. *World J Surg.* 2015;39:41–46.
5. Campbell A, Restrepo C, Mackay D, et al. Scalable, sustainable cost-effective surgical care: A model for safety and quality in the developing world, part II: Program development and quality care. *J Craniofac Surg.* 2014;25:1680–1684.
6. Campbell A, Restrepo C, Mackay D, et al. Scalable, sustainable cost-effective surgical care: A model for safety and quality in the developing world, part I: Challenge and commitment. *J Craniofac Surg.* 2014;25:1674–1679.
7. Campbell A, Restrepo C, Mackay D, et al. Scalable, sustainable cost-effective surgical care: A model for safety and quality in the developing world, part III: Impact and sustainability. *J Craniofac Surg.* 2014;25:1685–1689.
8. Cutting C, Oliker A, Haring J, Dayan J, Smith D. Use of three-dimensional computer graphic animation to illustrate cleft lip and palate surgery. *Comput Aided Surg.* 2002;7:326–331.
9. Flores RL, Deluccia N, Oliker A, McCarthy JG. Creating a virtual surgical atlas of craniofacial procedures: Part II. Surgical animations. *Plast Reconstr Surg.* 2010;126:2093–2101.
10. Flores RL, Deluccia N, Grayson BH, Oliker A, McCarthy JG. Creating a virtual surgical atlas of craniofacial procedures: Part I. Three-dimensional digital models of craniofacial deformities. *Plast Reconstr Surg.* 2010;126:2084–2092.
11. Flores RL. The smile train virtual surgery stimulator. Available at: https://smiletrain.biodigitalhuman.com/home. Accessed December 11, 2019.
12. Vyas RM, Eberlin KR, Patel KB, et al. International surgical outreach initiatives: Planning, execution, and safety. In: Rogers D, Hartnick CJ, Hamdan US, eds. *Video Atlas of Cleft Lip and Palate Surgery.* San Diego, Calif: Plural Publishing; 2013:17–38.
13. Eberlin KR, Vyas RM, Abi-Haidar Y, Sethna N, Hamdan US. Adult cleft lip repair under local anesthesia: An effective technique in resource-poor settings. *Cleft Palate Craniofac J.* 2013;50:59–63.
14. Eberlin KR, Zaleski KL, Snyder HD, Hamdan US; Medical Missions for Children. Quality assurance guidelines for surgical outreach programs: A 20-year experience. *Cleft Palate Craniofac J.* 2008;45:246–255.
15. Patel KG, Eberlin KR, Vyas RM, Hamdan US. Use of safety measures, including the modified World Health Organization surgical safety checklist, during international outreach cleft missions. *Cleft Palate Craniofac J.* 2014;51:597–604.
16. Vyas RM, Eberlin KR, Hamdan US. Implementation of an emergency response protocol for overseas surgical outreach initiatives. *Plast Reconstr Surg.* 2013;131:631e–636e.
17. Sayadi LR, Chopan M, Maguire K, et al. A novel innovation for surgical flap markings using projected stencils. *Plast Reconstr Surg.* 2018;142:827–830.
18. Terander AE, Burstrom G, Nachabe R, et al. Pedicle screw placement using augmented reality surgical navigation with intraoperative 3D imaging: A first in-human prospective cohort study. *Spine (Phila Pa 1976)* 2018;44:517–522.
19. Pokhrel S, Alsadoon A, Prasad PWC, Paul M. A novel augmented reality (AR) scheme for knee replacement surgery by considering cutting error accuracy. *Int J Med Robot.* 2019;15:e1958.
20. Umebayashi D, Yamamoto Y, Nakajima Y, Fukaya N, Hara M. Augmented reality visualization-guided microscopic spine surgery: Transvertebral anterior cervical foraminotomy and posterior foraminotomy. *J Am Acad Orthop Surg Glob Res Rev.* 2018;2:e008.
21. Davis MC, Can DD, Pindrik J, Rocque BG, Johnston JM. Virtual interactive presence in global surgical education: International collaboration through augmented reality. *World Neurosurg.* 2016;86:103–111.
22. Farmer PE, Kim JY. Surgery and global health: A view from beyond the OR. *World J Surg.* 2008;32:533–536.
23. Mathers CD, Loncar D. Projections of global mortality and burden of disease from 2002 to 2030. *PLoS Med* 2006;3:e442.
24. Voelker R. Experts say projected surgeon shortage a "looming crisis" for patient care. *JAMA* 2009;302:1520–1521.
25. Sheldon GF. Access to care and the surgeon shortage: American Surgical Association forum. *Ann Surg.* 2010;252:582–590.
26. Sheldon GF, Ricketts TC, Charles A, King J, Fraher EP, Meyer A. The global health workforce shortage: Role of surgeons and other providers. *Adv Surg.* 2008;42:63–85.